

Complex reconstruction changes a patient's life

By Jim Arnold, DDS

After years of not smiling and experiencing pain with chewing at every meal, Carmen decided to do something significant to change her life.

My team and I were excited to meet her because we knew that our work could help give her the smile, comfort and dental health she had always wanted.

Carmen had seen examples of our work on our website, so she felt confident that she was coming to the right place for her care.

Despite her confidence in us, however, she was still nervous about having major dental work done.

We did everything we could to relieve her anxiety and make the process as easy and comfortable as possible.

Patient history

Several teeth had been broken because of abuse from a former boyfriend, and she had severe dental pain due to the trauma and resulting malocclusion. Carmen had been a model as a teenager, but she had rarely smiled since the teeth had been broken (Fig. 1a).

In fact, she was so self-conscious that she rarely opened her mouth in public, and she never showed her teeth in photographs.

After eight years of living with little hope, she hoped to regain her smile, self-confidence and faith in people because of her experience with us.

She cried with gratitude when I told her that we could help her to regain the confidence, chewing

→ **CT** page 2C

Before ...



Fig. 1a: At her initial consultation, Carmen tries to smile for the camera.

After ...



Fig. 1b: Carmen is learning to smile again.

Collaborate at 2011 AACD

For the 27th consecutive year, the American Academy of Cosmetic Dentistry (AACD) will assemble the world's premier program of cosmetic dental educators. The 27th annual AACD Scientific Session, "The Rise of Collaboration," will take place in historic Boston from May 18-21.

The focus will be on integrated, side-by-side learning for the entire dental team.

"Collaboration is the key to success on the modern dental team," said AACD President Hugh Flax, DDS, of Atlanta.

"In order for dentists, technicians and team member to provide the comprehensive oral health care today's patients demand, dental professionals must develop and refine their skills together."

Collaborative learning in Boston

During the scientific session, attendees will learn the latest advancements in cosmetic dentistry through a variety of mediums intended to provide an in-depth, revolutionized learning experience.

Emerging technologies, new clinical techniques, team-based courses and practice management strategies are the basis for the world's premier cosmetic dental continuing education event.

Large-scale lectures offer a multi-disciplinary approach to continuing education and a broad perspective on evolving treatment techniques in cosmetic dentistry.

The AACD's in-depth, hands-on workshops are in high demand as attendees work one-on-one with esteemed educators alongside their colleagues. Materials and supplies are provided through corporate support.

Featured educators include:*

- Guiseppe Allais
- Stephen Chu, DMD
- Newton Fahl, DDS
- Willi Geller
- Harald Heymann, DDS, Med
- Frank Spear, DDS, MSD
- Dennis Tarnow, DDS
- Dennis Wells, DDS

AACDConference.com launched Registration and detailed event information for exhibitors and

attendees is now available online at www.aacdconference.com.

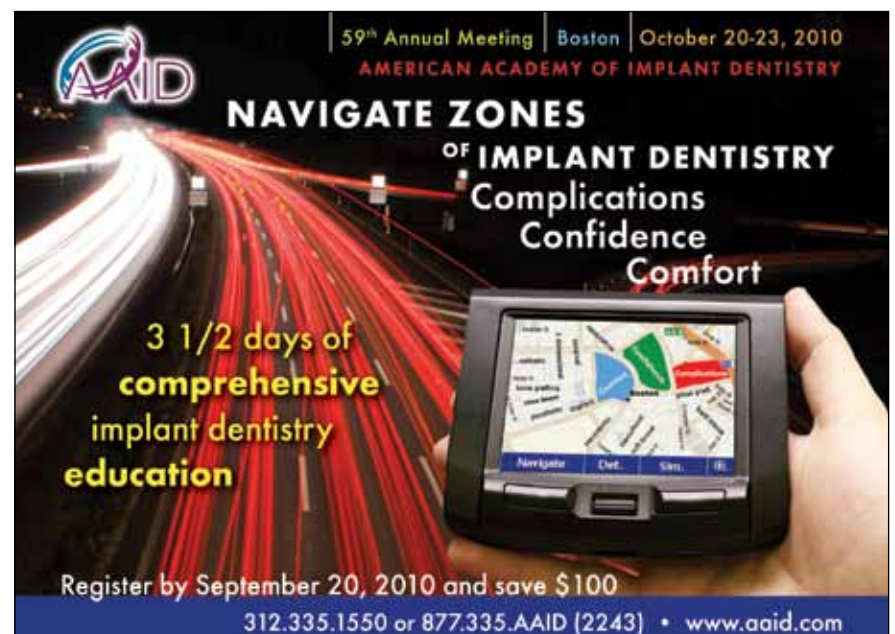
Highlights of the redesigned AACD conference home page include streamlined navigation, real-time updates of course content

and a photo directory of the speakers. **CT**

*Speakers are subject to change.

(Source: AACD)

AD



59th Annual Meeting | Boston | October 20-23, 2010
AMERICAN ACADEMY OF IMPLANT DENTISTRY

NAVIGATE ZONES
OF IMPLANT DENTISTRY
Complications
Confidence
Comfort

3 1/2 days of
comprehensive
implant dentistry
education

Register by September 20, 2010 and save \$100
312.335.1550 or 877.335.AAID [2243] • www.aaid.com

TV weatherman gets a smile makeover

By Fred Michmershuizen, Online Editor

Dr. Robin Rutherford, a cosmetic dentist with a practice called The Art of Dentistry located in Odessa, Texas, recently provided a smile makeover for Greg Morgan, a local TV meteorologist. The dental work was explained to viewers during a series that aired on CBS 7 News.

Viewers were able to witness one step of the dental treatment plan at a time — from the initial examination to the completed transformation.

Before the procedure, Morgan spoke of his love for making a difference in people's lives through laughter, but he also said he felt something was missing. "If I could feel more comfortable with the way I smile, I could just do my job that much better," Morgan told PRWEB.

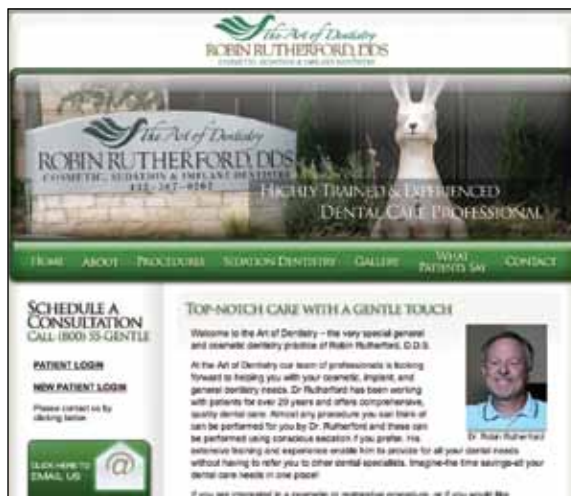In the final installment of the series, Morgan's new smile was revealed. He said that his favorite part about the whole process was enjoying the reactions he received to his new look.

During the series, Rutherford was able to showcase the experience he gained while traveling the United States studying with a number of leading cosmetic dentists practicing in the field today.

With access to such a wide base of knowledge, Rutherford said, he is able to provide comprehensive, quality dental care for nearly any patient regardless of the type of procedure required.

Rutherford works with a wide variety of techniques, which often include procedures such as dental implants or porcelain dental veneers.

Rutherford said the overall ease of the process was portrayed through Morgan's upbeat personality and sense of humor as he was seen sharing his



A screenshot of Dr. Robin Rutherford's website, www.gentledentaldoc.com.

personal experience with viewers until the final smile was revealed.

"Changing your smile can change your life," Rutherford said.

The series aired every morning and evening for an entire week in the spring of 2010. **CT**

← **CT** page 1C

function and comfort that she had lost many years ago.

Clinical examination findings

Our comprehensive evaluation included a full series of radiographs, digital photographs, clinical examination of the teeth and periodontium, diagnostic models and patient interview. Carmen's teeth were also severely affected by tetracycline staining.

Heavy attrition, deteriorating restorations and extensive decay added to the complexity of her restorative situation.

A lack of regular dental care and many years of smoking helped lead to moderate periodontal disease and the loss of several posterior teeth. Carmen's measurement from the cemento-enamel junction (CEJ) of the maxillary central incisors to the CEJ of the mandibular central incisors (Shimbashi measurement) was only 11 mm.

This was a result of the heavy wear on her remaining teeth (Figs. 2-4). A Shimbashi measurement of about 16 to 18 mm is typical for patients exhibiting Class I occlusion.

Initial periodontal protocol

We began Carmen's treatment by addressing her periodontal disease. Thorough oral hygiene instructions were given, scaling and root-planing appointments were scheduled immediately and she began rinsing with chlorhexidine twice daily. My hygienist thoroughly cleaned her

teeth under local anesthesia in two visits. Then we reevaluated her periodontal health four weeks later at the follow-up cleaning.

She had already improved dramatically. Pocket depths decreased significantly (from 4 to 5 mm down to 2 to 4 mm), bleeding upon probing was eliminated and her plaque score improved significantly. For the first time in many years, the gingival apparatus appeared to be pink and healthy. Now convinced of her commitment to maintaining her oral health, we proceeded with additional records to finalize our restorative treatment plan.

Diagnostic records and the restorative plan

Carmen's needs were extensive, so we opted to perform full-mouth rehabilitation to restore her natural form, function and esthetics. New diagnostic models were made in order to facilitate creation of a full diagnostic wax-up.

We made an NTI appliance for her to wear for several nights in order to deprogram (or relax) her tense masticatory muscles. This allowed us to obtain a more accurate centric relation (CR) measurement. Face-bow and stick-bite records were also made, and photographs were taken to aid our ceramist (Marv Staggs, Precision Dental Restorations [PDR]; Salem, Ore.). These records allowed him to accurately mount Carmen's models for a full-mouth wax-up.

We reviewed photographs from several smile guides with Carmen to decide how to design her new smile.

We determined what she wanted her new teeth to look like, selecting shapes, embrasures, line angles and texture. We also decided on the desired colors and incisal translucency to be utilized.

Local anesthetic was administered so we could "sound" the bone to see how much gingival recontouring we could do. We were able to improve gingival symmetry with our laser, and we made new PVS impressions.

After reviewing restorative options with our ceramist, we decided to restore Carmen's upper and lower arches with crowns and a bridge. Because strength and maximizing esthetics were both high priorities, we decided to use Empress (Ivoclar Vivadent; Amherst, N.Y.) crowns for teeth #4-#11 and #21-#29, and a Lava (3M ESPE) bridge for #12-#14. Her missing posterior teeth would be restored later with implants or removable partials.

First restorative appointment

At the preparation appointment, we evaluated the wax-up with Carmen, and we were all very pleased. We therefore proceeded with her restorative treatment.

We modified several teeth with reduction models provided by PDR so that we could preoperatively transfer the wax-up to the mouth with Luxatemp (Zenith/DMG; Englewood, N.J.). This gave us a tool for verification of our records, desired lengths of teeth, CEJ-to-CEJ measurements, proper canine and anterior guidance and occlusion.

COSMETIC TRIBUNE

The World's Dental Newspaper - US Edition

Publisher & Chairman

Torsten Oemus
t.oemus@dental-tribune.com

Vice President Global Sales

Peter Witteczek
p.witteczek@dental-tribune.com

Chief Operating Officer

Eric Seid
e.seid@dental-tribune.com

Group Editor & Designer

Robin Goodman
r.goodman@dental-tribune.com

Editor in Chief Cosmetic Tribune

Dr. Lorin Berland
d.berland@dental-tribune.com

Managing Editor/Designer

Implant, Endo & Lab Tribunes
Sierra Rendon
s.rendon@dental-tribune.com

Managing Editor/Designer

Ortho Tribune & Show Dailies
Kristine Colker
k.colker@dental-tribune.com

Online Editor

Fred Michmershuizen
f.michmershuizen@dental-tribune.com

Account Manager

Mark Eisen
m.eisen@dental-tribune.com

Marketing Manager

Anna Wlodarczyk
a.wlodarczyk@dental-tribune.com

Sales & Marketing Assistant

Lorrie Young
l.young@dental-tribune.com

C.E. Manager

Julia E. Wehkamp
j.wehkamp@dental-tribune.com

Dental Tribune America, LLC
215 West 35th Street, Suite 801
New York, NY 10001
Tel: (212) 244-7181
Fax: (212) 244-7185

Published by Dental Tribune America
© 2010 Dental Tribune America, LLC
All rights reserved.

Cosmetic Tribune strives to maintain utmost accuracy in its news and clinical reports. If you find a factual error or content that requires clarification, please contact Group Editor Robin Goodman at r.goodman@dental-tribune.com.

Cosmetic Tribune cannot assume responsibility for the validity of product claims or for typographical errors. The publisher also does not assume responsibility for product names or statements made by advertisers. Opinions expressed by authors are their own and may not reflect those of Dental Tribune America.

Tell us what you think!

Do you have general comments or criticism you would like to share? Is there a particular topic you would like to see articles about in Cosmetic Tribune? Let us know by e-mailing feedback@dental-tribune.com. We look forward to hearing from you!

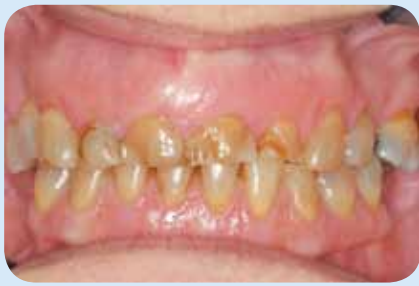

Fig. 2

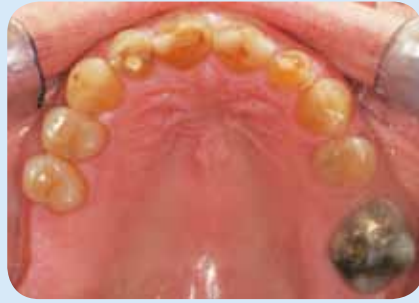

Fig. 3

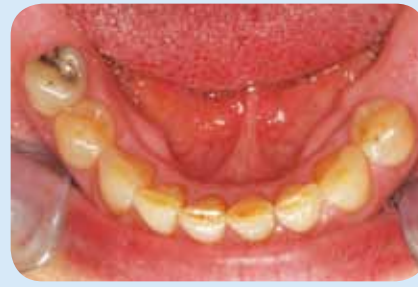

Fig. 4

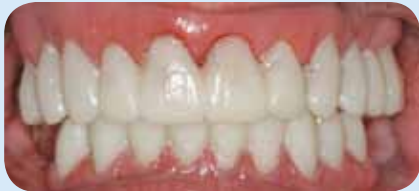

Fig. 5

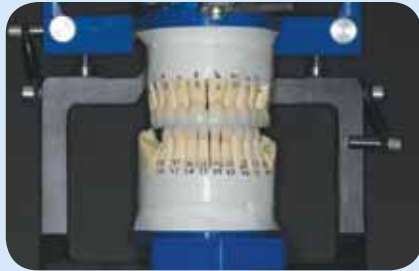


Fig. 6

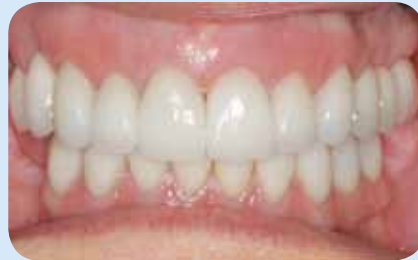

Fig. 7

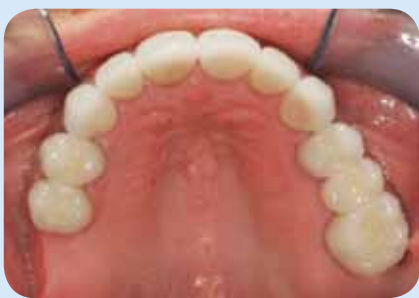

Fig. 8

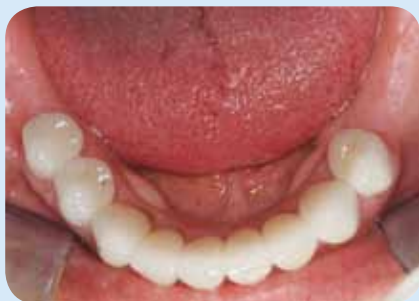

Fig. 9



Fig. 10

Fig. 2: Carmen's broken and heavily worn teeth make it hard for her to eat and smile.

Fig. 3: Her maxillary teeth are heavily worn, have large restorations and significant recurrent decay.

Fig. 4: Her mandibular teeth are significantly shortened by heavy wear.

Fig. 5: Carmen's new temporaries make her feel better already.

Fig. 6: The new porcelain restorations are evaluated for esthetics, fit, lengths and occlusion on the articulator.

Fig. 7: Carmen's beautiful new restorations give back her smile and allow her to chew comfortably for the first time in years.

Fig. 8: The new maxillary porcelain restorations restore broken, decayed and worn-down teeth.

Fig. 9: The mandibular restorations add length and improve overall esthetics and function.

Fig. 10: Learning to smile again.

The full-mouth Luxatemp mock-up also served as an ideal intraoral preparation guide so that depth cuts could be made into the Luxatemp and tooth structure. This allowed us to maintain even reduction and ideal orientation within the arch form. We segmentally prepared all maxillary teeth, making bite registrations (LuxaBite, Zenith/DMG) for the anterior, right side and left side, allowing us to maintain the new vertical dimension that had been established with the mock-up.

After the maxillary preparations were completed, we checked the preparation shades, took photographs and made a maxillary final impression.

We used the Sil-Tech stint to make ideal temporaries, and the CEJ-to-CEJ measurements and tooth lengths were again verified.

Sequential bite registration records were again used while prepping the lower arch for the anterior and both posterior sections.

We systematically recorded the relationship from the lower to upper preparations and the lower preparations to the upper temporaries. This helped to ensure that all models could be easily cross-mounted by the laboratory and that the new vertical dimension was maintained.

We made the mandibular impression and temporized #21-#29 with Luxatemp. We then recorded the bite relationship between the maxillary preparations and the mandibular temporaries. After temporarily cementing the maxillary temps, we recorded the bite relationship between the upper and lower temps.

Facebow record and stick bites were also made, and photographs of each were taken. We completed the preparation appointment with photographs and PVS impressions of the temporaries (Fig. 5).

All of the relevant photos were sent to PDR on a disc, along with the laboratory prescription, impressions, bite registrations and models. We provided detailed instructions for completing her case.

Trial period with temporaries

Our goal was to restore Carmen to a Shimhashi measurement of 17 mm to allow for ideal function, comfort and maximum esthetics. Her occlusion was restored to CR in the temporary stage, and she adapted to the temporaries very well.

If she had any issues with the increased vertical dimension, we could have adjusted her temporaries to a position of greater comfort while maintaining proper function.

Her self-confidence increased dramatically with her temporary restorations, and she found herself smiling more than ever. Carmen was looking forward to a new future filled with hope and happiness, and her inner joy was reflected on the surface.

Seating the case

Evaluation of her new restorations on the articulator confirmed that the fit, lengths, esthetics, occlusion and color were all exactly as prescribed (Fig. 6).

When she arrived for her seat appointment, she was still very comfortable, so a little more than three

months after our first consultation we were ready to deliver her beautiful porcelain restorations (Figs. 7-9).

We removed the maxillary temporaries and cleaned up the prepared teeth after administering local anesthesia. We tried in each restoration individually and collectively, and everything fit very well. The maxillary restorations also occluded well with the mandibular temporaries. After determining that we both preferred the translucent shade of RelyX (3M ESPE), the maxillary restorations were bonded utilizing standard bonding protocol and the "tack-and-wave" technique.

The maxillary restorations were fully seated at the same time and were individually "tacked" in with the Bluephase (Ivoclar Vivadent) curing light with tacking tip for one second each.

The standard tip was then used in order to "wave" across the arch for a few seconds on the facial and lingual sides, hardening the cement to the point where the gross excess could be simply removed.

Liquid Strip (Ivoclar Vivadent) was placed around all of the margins (to ensure that the oxygen-inhibition layer cured completely), we flossed carefully and final curing was completed. The lower arch was anesthetized, and maxillary cleanup was completed.

We removed the mandibular temporaries and utilized the same try-in and seating techniques that we used in the maxillary arch.

Occlusion was adjusted slightly, photographs were taken and post-operative instructions were given.

Seeing her new smile in the mirror elicited tears of joy for Carmen (Fig. 10). **CT**

About the author



Dr. Jim Arnold serves on the advisory board for the Academy of Comprehensive Esthetics while balancing his time between three busy dental practices, his four children and triathlon training.

In 2008, the American Academy of Cosmetic Dentistry awarded Arnold with the Partners in Peace Award for his extensive work with the Give Back a Smile program.

James H. Arnold, D.D.S.
drarnold@smilesbyarnold.com
www.SmilesByArnold.com
 (219) 926-5445